



DOI: <http://dx.doi.org/10.31759/mej.2023.7.2.045>

A histological study on the use of immobilized algae as a bioremedators to amoxicillin in *Pseudodontopsis euphraticu*

Jasim Mohammed Salman¹ Zahraa H. Obaid² Nuha F. Kadhim³

¹ Department of Biology, College of Science, University of Babylon, Iraq.

ORCID: <https://orcid.org/0000-0002-2130-7197>

²Environmental Research& Study Center, University of Babylon,Iraq.,

ORCID: : <https://orcid.org/0000-0003-1558-1680>

³ Department of Biology, College of Science, University of Babylon, Iraq.

ORCID: <https://orcid.org/000-0003-3101-2891>

*Corresponding Author: jasimsalman@uobabylon.edu.iq

To cite this article:

Salman J. M ; Obaid Z. H.; Kadhim N. F.. A histological study on the use of immobilized algae as a bioremedators to amoxicillin in *Pseudodontopsis euphraticu*. *Mesop. environ. j.*, 2023, Vol.7, No.2, pp. 36-45.

Received date: 2/10/2023

accepted date: 29/12/2023

published date:31/12/2023

This work is licensed under a [Creative Commons Attribution-NonCommercial-NoDerivatives 4.0](https://creativecommons.org/licenses/by-nc-nd/4.0/)



Abstract:

Antibiotics in the aquatic environment have a negative impact on non-target aquatic organisms. The current study intends to evaluate the effects of the toxicity of the amoxicillin antibiotic and the contribution of immobilized *Chlorella vulgaris* to decreasing toxicity by observing histological changes in the clam *Pseudodontopsis euphraticus*. The results demonstrated that seven days of exposure to amoxicillin in different concentrations of 100, 200, and 300 mg/L caused significant histological changes, including cell infiltration, haemocytosis, cell degeneration, large lymphatic spaces between the tubes, necrosis of the cells of the digestive glands, and narrowing of the tubular lumen, while histological changes to the gills included an anterior fusion of the cilia, hyperplasia of cells, infiltration of blood cells, necrosis, and rupture of epithelial cells specially in concentrations of 200 and 300 mg/L. The results of the present study showed that immobilized *C. vulgaris* contributed effectively to reducing amoxicillin toxicity by alleviating the histological changes in freshwater clams *P. euphraticus*. The aim of the study was to use histological changes to evaluate the use of immobilized algae in reducing the toxic effect of amoxicillin on *Pseudodontopsis euphraticus*

Keywords: histological, *Pseudodontopsis euphraticus*, Immobilized algae, Amoxicillin.

Introduction

Amoxicillin (AMX) is an antibiotic widely utilized in both human and veterinary medicine around the globe. This medicine has been discharged into the environment at levels vary from ng L^{-1} to $\mu\text{g L}^{-1}$ due to its extensive manufacturing and use [1]. Antibiotics are clarified as an emerging pollutant because of the serious harm they cause to aquatic organisms, as abnormalities of embryonic development, histological changes, increased oxidative stress, etc. the most important environmental problem for antibiotics in an aquatic system is the emergence of bacteria and antibiotic resistance genera that kill 700,000 people each year. [2].

C. vulgaris is a promising environmental option for the removal of emerging contaminants such as antibiotics from aquatic environments due to its ability to withstand oxidative stress through its physiological susceptibility to the decomposition of various pollutants, it has rapid growth, and high tolerance to difficult environmental conditions such as salinity and heat [3][34]. Algae immobilization technology is gaining popularity and is being used in a variety of environmental applications, including wastewater treatment by removing pharmaceuticals, nutrients, dyes, and heavy metals. [4][32].

The of bivalve mollusks are widely used as reliable indicators to determine the types and concentrations of several pollutants in different aquatic systems [5]. This is due to its possession of many important features such as wide distribution, abundance, stable behavior, physical size, filter feeding, and ease of breeding in the laboratory [6][33]. Histopathology is utilized as a reference standard for assessing the sensitivity and specificity of organisms to different species of contamination, and there are important correlations between histological alterations and environmental stress [7].

Histological studies are one of the most appropriate possible biomarkers because they measure response to short and long periods of exposure pollution, use many tissues, are distinguishable, and can be effective [8]. Histopathological changes in tissues were identified accurate biomarkers for differentiating contamination levels in various aquatic environment[9].

The present study aims to evaluate the detrimental effect of amoxicillin on histological biomarkers in freshwater clams, *Pseudontopsis euphraticus*, and reduce these effects by using immobilized *C. vulgaris* as an environmentally friendly method.

Material & Methods:

Sample collection and identification

A *P. euphraticus* clam sample has been obtained from the Euphrates River, approximately 20 kilometers west of the city of Hilla and approximately the same distance east of the city of Karbala, in the Al-Hindiya region "(32°32' 29.9 N, 44°13' 38.7 E)", figure 1, to be used in toxicity testing. The clam species selected for the current experiment were diagnosed by the Center for Marine Sciences at the University of Basra.

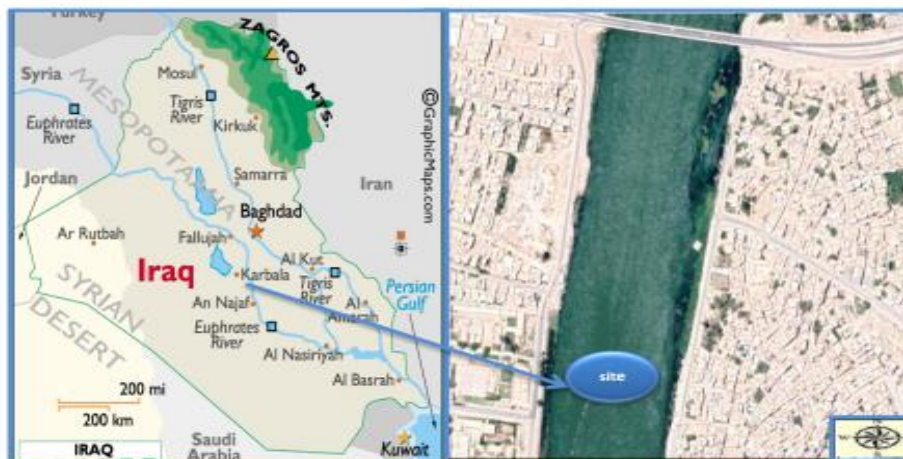

Figure (1): Satellite Image of sampling sites (Euphrates River)

Immobilized Method

The microalgae (*Chlorella vulgaris*) sample was acquired by the "Environmental Research and Studies Center, University of Babylon, Iraq." For the preparation of immobilized *C. vulgaris*, 50 mL of *C. vulgaris* in stationary phase was taken on days 12 and 14 and then condensed by centrifugation for 3 min at 3000 rpm (Hettich). Then, the concentrated algae were collected, mixed with an equivalent amount of 2% sodium alginate solution, and then pulled into a medical syringe or separation funnel, after which the mixture was dripped drop by drop into a beaker containing calcium chloride at a concentration of 3% and gently stirred for 1–2 min. It will form beads, after which they are thoroughly rinsed using distilled water by a strainer for tea to remove the granules formed from the CaCl_2 solution. After that, they are kept in distilled water in a cool place [10][11].

Pharmaceutical Material

Amoxicillin trihydrate, $\text{C}_{16}\text{H}_{19}\text{N}_3\text{O}_5\text{S}$, used in this study was gotten from "General Company for the Manufacture of Medicines and Medical Supplies Samarra, Iraq".

Design of Experiments

Freshwater clams, *P. euphraticus*, with shell lengths that varied from 3.5 to 4.6 cm, were from the Euphrates River and transferred to the laboratory. It was putted in 24 plastic containers, with dimensions of (18x21x31)cm. They were acclimatized for five days with dechlorinated water, after which they were exposed to amoxicillin at doses of 100, 200, and 300 mg/l for seven consecutive days, and immobilized *C. vulgaris* (5–15 beads) was put in all amoxicillin-treated containers.

Histological Biomarkers

To make histological sections, digestive tract and gills were collected from mollusks after the end of experiment and preserved in formaldehyde (10%) [12]. utilizing a graded ethanol series (70-100%) to dehydrating and paraffin embedded; 5–8 μm thicknesses were taken using a Leitz 1512 microtome, and it was stained with hematoxylin and eosin (H&E), and histological sections are examined using an Olympus microscope (Leica DMi9) equipped with a digital camera [13][14].

Results and Discussion

Histological changes of digestive tract in *P. euphraticus*

Cell morphological monitoring is a fundamental strategy in toxicological investigations [15]. Such observations can reveal histopathological alterations in an organism following contaminants exposure. The digestive gland of bivalves is an important organ for metabolism and bioaccumulation, and its epithelial cells covering digestive tubules are sensitive to the detrimental impacts of a variety of contaminants [16]. The digestive tract, which is crucial, is involved in nutrition absorption, hormone production, energy metabolism, and immunological protection [17]. In clams, the digestive tract has one layer of epithelial cells surrounded by a virtually occluded lumen, basophilic cells, digestive lumen, basement membrane, hemolymphatic gap between tubules, and connective tissue [18], as shown in Figure 2.

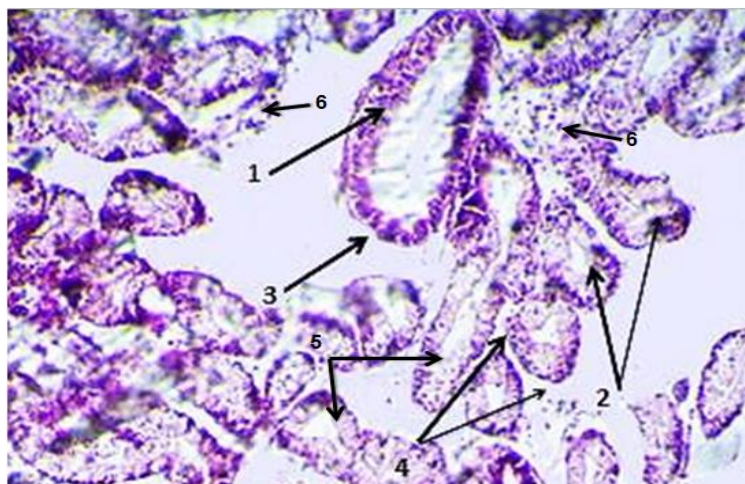


Figure (2): histological Section of the digestive tract for *P. euphraticus* (control) 1. basophilic cell, 2. digestive lumen, 3. basement membrane, 4. hemolymphatic gap between tubules, 5. typical tubules, 6. connective tissue, (H & E, Scale bar; 10X).

Following the exposure to AMX, Microscopic examinations revealed significant changes in the digestive tract cells (Figure. 3). The clams treated with a concentration of 200–300 mg/L amoxicillin showed a variety of histological abnormalities, including shrinkage of epithelial cells, an expanded nucleus, enlarged vacuoles, and increased hemolymphatic gaps. Hemolytic infiltration of connective tissue was slightly at 200 mg/L concentrations. but acute degeneration of digestive tubules and necrosis of epithelial cells were seen at a 300mg/L concentration. In the case of adding immobilized *C. vulgaris*, it was observed that histological changes were less in clams as seen in Figure 4.

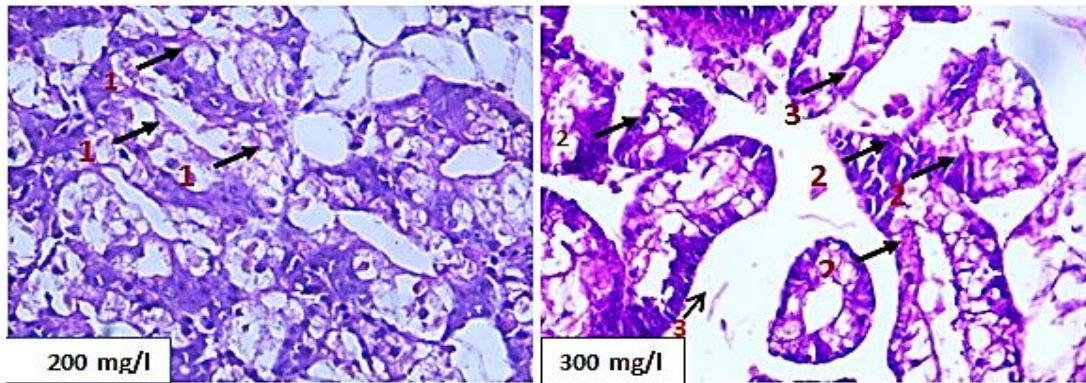


Figure (3): Cross section of the *P. euphraticus* clams digestive tract , showed 1. shrinkage epithelial cells, swollen nucleus, 2. cells enlarged vacuoles ,3. enlarged hemolymph spaces, (without *C.vulgaris*) .H & E, Scale bar 40x

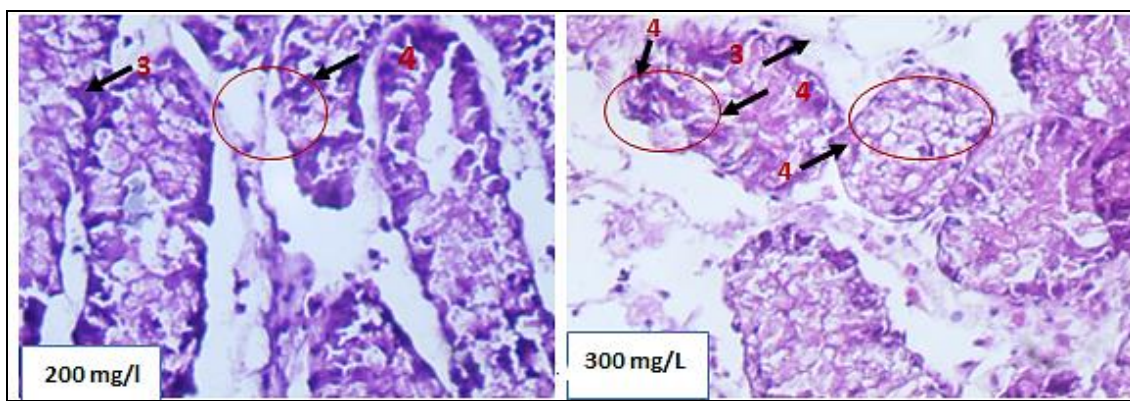


Figure (4): Cross section of *P. euphraticus* digestive tract shown 3.enlarged hemolymph spaces ,4. basophilic triangular shaped cell present in the connective tissue among the tubule,(with *C.vulgaris*), H & E, Scale bar 40x .

Histological changes of gills in *P. euphraticus*

Gills are the first point of contact between bivalve mollusks and an aquatic environment and play an important role in feeding and respiration processes in molluscs. These structures are therefore significantly vulnerable to different environmental stresses[19]. represented in the control samples consist of the gill filaments with a normal density of ciliated epithelial cells, as shown Figure 5.

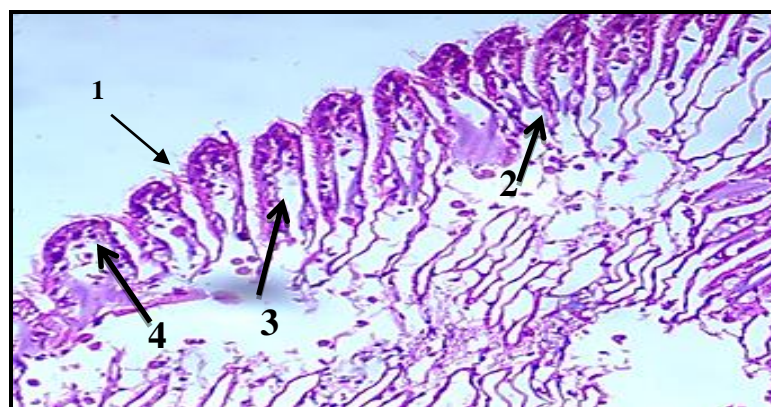


Figure (5): histological section of gills in clams *P. euphraticus* (control): 1. Cilia, 2. Haemocoelic Space, 3. Ventral Epithelia, 4. Dorsal Epithelia, (H & E, Scale bar 10X).

After exposure to AMX, clear histological changes appeared in the gills, and these changes were proportionate to the rise in concentration. Particularly after exposure to a concentration of 300 mg/l, and these changes included epithelial elongating, secondary lamellar rupturing, curling of secondary lamellae, hyperplastic interlamellar epithelium, and hemocytes necrosis, as shown in Figure 6. In the case of adding immobilized *C. vulgaris*, it was observed that histological changes were less in clams as seen in Figure 7.

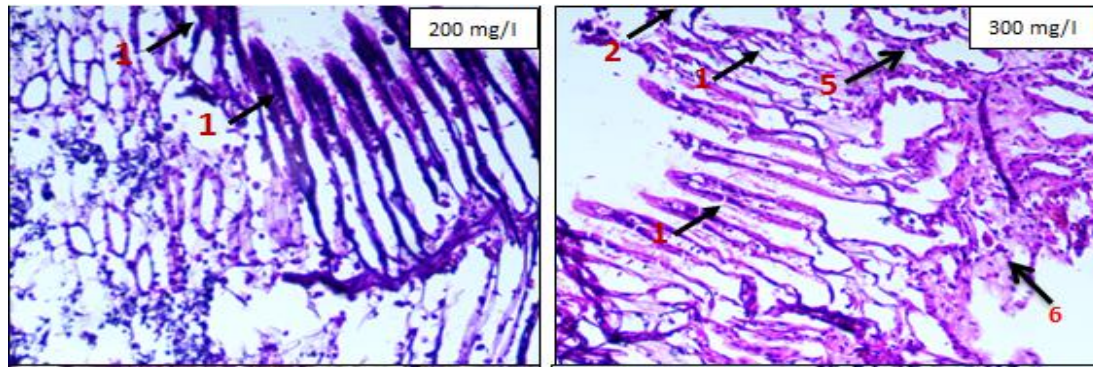


Figure (6): Cross section of clams *P. euphraticus*, showed 1. epithelial elongating ,secondary lamellar rupturing ,3. curling of secondary lamellae ,4. hyperplastic interlamellar epithelium,5. hemocytes necrosis 6, haemocytes (H & E, Scale bar 10X) , (without *C. vulgaris*)

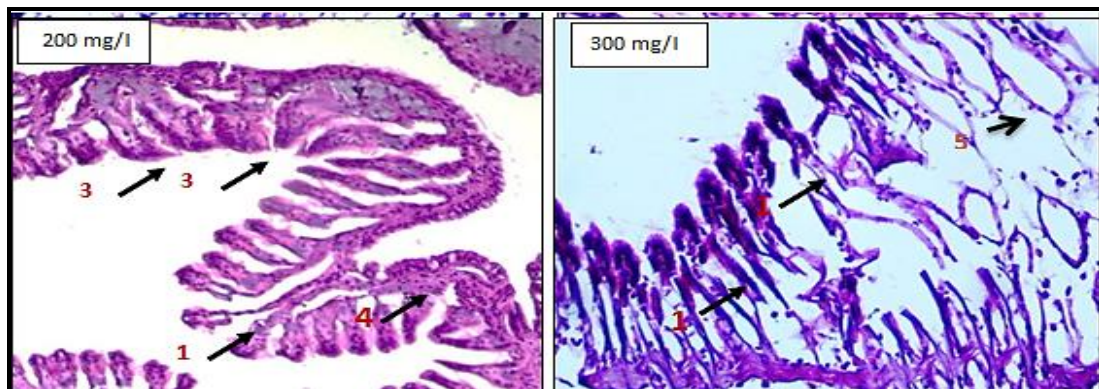


Figure (7): Cross section of clams *P. euphraticus*, showed 1. epithelial elongating,secondary lamellar rupturing ,3. curling of secondary lamellae ,4. Hyperplastic interlamellar epithelium,5. hemocytes necrosis (H & E, Scale bar 10X) ,(with *C. vulgaris*)

Histological malformation analysis is a popular tool to evaluate the impact of toxicants and the environment[19]. The utilization of gills and digestive tract in this study is currently due to their importance in the metabolization of contaminants such as medicines and detoxification processes. Because the gills and digestive tract are target tissues for numerous pollutants, they were chosen to evaluate the drug's impacts. The digestive tract are primarily responsible for the collection and metabolism of organic substances [20]. Necrotic cell death and excessive vacuole formation are common diseases of muscle tissue due to exposure to toxins in clams [21] . In a current study, the hyperplasia in digestive tract sections treated with AMX was observed The increase in the concentration of toxic substances such as drugs, pesticides, etc. blocks the normal metabolic processes of the cells within The increase in the

concentration of toxic substances such as drugs, pesticides, etc. blocks the normal metabolic processes of the cells within the tissues, which causes hyperplasia, cellular inequality, and cell death [22].

Observation in this study agree with many studies, such as those studied by Rodrigues et al.'s histopathological impact of anti-erythromycin on *Oncorhynchus mykiss*, which caused gradual gill histological changes such as mucosal hyperplasia, hyperplasia of the epithelial cells, and hypertrophy of mucous cells [23]. Similar histological changes in the gill tissue of *Corbicula fluminea* were observed because of Bisphenol-A exposure, which also caused histological changes in muscle soft tissues in clams [24]. The formation of vacuoles and necrotic cell death are pathological signs in the muscle tissue of an organism as a result of a response to toxic substances [25]. Stalin *et al.* exhibit the same histological abnormalities in the gills of *Lamellidens marginalis* after chlorpyrifos exposure, including enlarged gill filaments, necrosis, lamellar fusion, and structural alterations [26]. When compared to the control group, the degree of damage in the gill tissues and digestive tract due to exposure to AMX depended on the exposure period and concentration of amoxicillin, and this study agrees with what was indicated by [27].

The present study shows that there is a link between acute exposure to the antibiotic amoxicillin and the histological changes observed in different tissues of clams, due to the AMX induces increased Reactive Oxygen Species ROS production that leads to oxidative stress in *P. euphraticus* and thus the occurrence of histological changes in clams. [28][29]. that Tebcoconazole- induced histological harm in the digestive tract and gills which increased with time and dose in the Mediterranean mussel *Mytilus*. Whereas in an experiment treated with *C. vulgaris* inhibitor, histological changes may have been less severe, possibly due to the ability of this type of algae to degrade these chemicals and convert them into less dangerous compounds, thus reducing the oxidative stress of the clams [30][31][32].

Conclusion

According to the findings of this study, antibiotics such as AMX can cause a range of mild to severe histological changes in *P. euphraticus* clams, depending on the concentration. This is due to amoxicillin's ability to cause an increase in the production of ROS reactive oxygen species in clams, resulting in increased oxidative stress and significant histological alterations in *P. euphraticus*. A recent study demonstrated the ability of immobilized *C. vulgaris* to reduce histological effects in clams due to the fact that immobilized *C. vulgaris* has a great capacity to adapt to aquatic environments containing pharmaceutical preparations; it also has a number of mechanisms as bioadsorption, bioaccumulation and biodegradation, that enable it to remove antioxidants, thus reducing oxidative stress. More researches are required to see if immobilized *C. vulgaris* can lessen the harmful effects of different antibiotics on non-target aquatic organisms, as well as an investigation into the mechanisms of removal of these pollutants by algae.

Author Contribution

All authors worked together to complete this project. Z.H.O. diagnosed, collected samples, performed the tests, and made histological sections. The draft was written, edited, and revised by J. M. S., and N. F. K. reviewed the information in order to make changes. The final paper was approved by all authors.

Declaration of competing interest

The author confirms that there was no competing interest with others.

Acknowledgements

The researchers would like to express their gratitude to the Department of Biology at the College of Science for their cooperation with this study.

Reference

- [1] Orozco-Hernández, J. M., Oliván, L. M. G., Heredia-García, G., Luja-Mondragón, M., Islas-Flores, H., SanJuan-Reyes, N., ... & Dublán-García, . genotoxic and cytotoxic alterations induced by environmentally-relevant concentrations of amoxicillin in blood cells of cyprinus carpio. *Chemosphere*, 2019, 236: 124323. . DOI :<https://doi.org/10.1016/j.chemosphere.2019.07.054>
- [2] González-González, E. D., Gómez-Oliván, L. M., Islas-Flores, H., & Galar-Martínez, M. .Developmental effects of amoxicillin at environmentally relevant concentration using zebrafish embryotoxicity test (ZET). *Water, Air, & Soil Pollution*, 232(5), 196. 2021. DOI: <https://doi.org/10.1007/s11270-021-05148-6>
- [3] Salem OMA, Abdelsalam A, Boroujerdi A. Bioremediation potential of chlorella vulgaris and nostoc paludosum on azo dyes with analysis of metabolite changes. *Baghdad Sci. J.* 18(3):454–64 . .2021. DOI: <http://dx.doi.org/10.21123/bsj.2021.18.3.0445>
- [4] Salman JM, Kaduem NF, Juda SA. Algal immobilization as a green technology for domestic wastewater treatment. *IOP Conf. Ser: Earth Environ Sci.* 1088 : 012005. 2022. [doi:10.1088/1755-1315/1088/1/012005](https://doi.org/10.1088/1755-1315/1088/1/012005)
- [5] El-Gendy KS, Gad AF, Radwan MA. Physiological and behavioral responses of land molluscs as biomarkers for pollution impact assessment: A review. *Environ Res.* 193:110558, 2021; [doi: 10.1016/j.envres.2020.110558](https://doi.org/10.1016/j.envres.2020.110558).
- [6] Zaidi M, Athmouni K, Metais I, Ayadi H, Leignel V. The Mediterranean limpet *Patella caerulea* (Gastropoda, Mollusca) to assess marine ecotoxicological risk: a case study of Tunisian coasts contaminated by metals. *Environ. Sci. Pollut. Res.* ,29(19):28339–58.2022. [doi: 10.1007/s11356-021-18490](https://doi.org/10.1007/s11356-021-18490)
- [7] Ijomah, O. O., Adesuyi, A. A., Njoku, K. L., Ojokuku, S. A., Moses, U. D., & Adesuyi, O. O. Histopathological effects and biomarker response of earthworms, *Eisenia fetida*, after exposure to crude oil contaminated soils. *Environmental analysis, health and toxicology*, 35(4) Impact. Nova Science Publishers, . Inc.pp542. 2020. DOI: [10.5620/eaht.2020021](https://doi.org/10.5620/eaht.2020021)
- [8] Carvalho, T. L. A. D. B., Nascimento, A. A. D., Gonçalves, C. F. D. S., Santos, M. A. J. D., & Sales, A. Assessing the histological changes in fish gills as environmental bioindicators in Paraty and Sepetiba bays in Rio de Janeiro, Brazil. *Latin american journal of aquatic research*, 48(4), 590-601. 2020. DOI: [org/10.3856/vol48-issue4-fulltext-2351](https://doi.org/10.3856/vol48-issue4-fulltext-2351)
- [9] Abdel-Moneim, A. M., Al-Kahtani, M. A., & Elmenshawy, O. M. Histopathological biomarkers in gills and liver of *Oreochromis niloticus* from polluted wetland environments, Saudi Arabia. *Chemosphere*, 88(8), 1028-1035. 2012. DOI: <https://doi.org/10.1016/j.chemosphere.2012.04.001>
- [10] Haider Z, al Mosawi A, Omran A, Ajanabi H, Mohammed A, al Mamoori J. Immobilize Algae To Removal Copper And Lead From Aquatic Ecosystem. *Nat Volatiles Essent Oils*.2022.
- [11] Adlercreutz P, Mattiasson B. Oxygen supply to immobilized cells. *Appl Microbiol Biotechnol.* 16(4):165–70. 1982. DOI: <https://doi.org/10.1007/BF00505826>

- [12] Parolini, M., De Felice, B., Gazzotti, S., Annunziata, L., Sugni, M., Bacchetta, R., & Ortenzi, M. A. Oxidative stress-related effects induced by micronized polyethylene terephthalate microparticles in the *Manila* clam. *Journal of Toxicology and Environmental Health, Part A*, 83(4), 168-179. 2020. DOI: <https://doi.org/10.1080/15287394.2020.1737852>
- [13] Wilson, I., Gamble, M., .The hematoxylin and eosin. In: Bancroft, J.D., Gamble, M. (Eds.), *Theory, Practice of Histological Techniques*. Churchill Livingstone- Elsevier Science Ltd., London, UK, p. 796. 2002.
- [14] Howard, D. W. *Histological techniques for marine bivalve mollusks and crustaceans* (Vol. 5). NOAA, National Ocean Service, National Centers for Coastal Ocean Service, Center for Coastal Environmental Health and Biomolecular Research, Cooperative Oxford Laboratory. 2004.
- [15] Wu, Y., Gu, E., Li, H., Tian, C., Feng, C. Oxidative stress and histological changes in *Corbicula fluminea* exposed to nano-Al13 and monomeric Al coagulants. *Environmental Science: Nano* 6, 2736-2748. 2019.
- [16] Vale, G., Franco, C., Diniz, M.S., Santos, M.M.C.D., Domingos, R.F. Bioavailability of cadmium and biochemical responses on the freshwater bivalve *Corbicula fluminea*–the role of TiO₂ nanoparticles. *Ecotoxicology and Environmental Safety* 109, 161-168. 2014.
- [17] Zhang L., Wang X., Zhang W., Yin X., Liu Q., Qiu L. .Impact of ocean acidification on physiology and microbiota in hepatopancreas of pacific oyster *Crassostrea gigas*. *J. Oceanol Limnol.* 40, 620–633. 2022. doi: 10.1007/s00343-021-0462-x. DOI: <https://doi.org/10.1007/s00343-021-0462-x>
- [18] Liang, J., Liu, Y., Zhu, F., Li, Y., Liang, S., & Guo, Y. Impact of ocean acidification on the physiology of digestive gland of razor clams *Sinonovacula constricta*. *Frontiers in Marine*. 2022. DOI: <https://doi.org/10.3389/fmars.2022.1010350>
- [19] Hussain, M., Hossain, M. A., Begum, M., & Roy, N. C. Freshwater mussel (*Lamelliedens marginalis*) to reduce the lead (Pb) bioaccumulation in aquaculture of stinging catfish, *Heteropneustes fossilis*. *Journal of Applied Aquaculture*, 1-17. 2022. DOI: <https://doi.org/10.1080/10454438.2021.2010630>
- [20] Trombini, C., Hampel, M., & Blasco, J. Assessing the effect of human pharmaceuticals (carbamazepine, diclofenac and ibuprofen) on the marine clam *Ruditapes philippinarum*: An integrative and multibiomarker approach. *Aquatic Toxicology*, 208, 146-156. 2019. DOI: <https://doi.org/10.1016/j.aquatox.2019.01.004>
- [21] Alonso, A., Suárez, P., Ruiz, Y., Dobal, V., & San Juan, F. Gonadal histopathological disorders in *Mytilus galloprovincialis* male exposed to tars used in mussel farms. *Frontiers in Marine Science*, 6, 577. 2019. DOI: <https://doi.org/10.3389/fmars.2019.00577>
- [22] Hossain, M. A., Sarker, T. R., Sutradhar, L., Hussain, M., & Iqbal, M. M. Toxic effects of chlorpyrifos on the growth, hemocytes counts, and vital organ's histopathology of freshwater mussel, *Lamellidens marginalis*. *Journal of King Saud University-Science*, 35(2), 102482. 2023. DOI: <https://doi.org/10.1016/j.jksus.2022.102482>
- [23] Rodrigues, S., Antunes, S. C., Nunes, B., & Correia, A. T. Histopathological effects of the antibiotic erythromycin on the freshwater fish species *Oncorhynchus mykiss*. *Ecotoxicology and Environmental Safety*, 181, 1-10. 2019. DOI: <https://doi.org/10.1016/j.ecoenv.2019.05.067>
- [24] Benjamin, K. B., Co, E. L., Competente, J. L., & de Guzman, D. G. H. Histopathological effects of bisphenol A on soft tissues of *Corbicula fluminea* Mull. *Toxicology and Environmental Health Sciences*, 11, 36-44. 2019. DOI: <https://doi.org/10.1007/s13530-019-0386-4>
- [25] Alonso, A., Suárez, P., Ruiz, Y., Dobal, V., & San Juan, F. Gonadal histopathological disorders in *Mytilus galloprovincialis* male exposed to tars used in mussel farms. *Frontiers in Marine Science*, 6, 577. 2019. DOI: <https://doi.org/10.3389/fmars.2019.00577>

- [26] Stalin, A., Gokula, V., & Amanullah, B. Effect of chlorpyrifos on biochemical changes in freshwater mussel *Lamellidens marginalis*. *Int J Appl Res*, 3(8), 157-59. 2017.
- [27] Tresnakova, N., Famulari, S., Zicarelli, G., Impellitteri, F., Pagano, M., Presti, G., ... & Faggio, C. Multi-characteristic toxicity of enantioselective chiral fungicide tebuconazole to a model organism Mediterranean mussel *Mytilus galloprovincialis* Lamarck, 1819 (Bivalve: Mytilidae). *Science of the Total Environment*, 862, 160874. 2023. DOI:<https://doi.org/10.1016/j.scitotenv.2022.160874>
- [28] Ndlela, L. L., Schroeder, P., Genthe, B., & Cruzeiro, C. Removal of Antibiotics Using an Algae-Algae Consortium (*Chlorella protothecoides* and *Chlorella vulgaris*). *Toxics*, 11(7), 588. 2023. DOI:<https://doi.org/10.3390/toxics11070588>
- [29] Obaid, Zahraa H., Nuha F. Kadhim, and Jasim Mohammed Salman. The Role of *Chlorella vulgaris* in Reducing Some Pharmaceutical Wastes Toxicity in Clam *Pseudodontopsis euphraticus*. *Baghdad Science Journal*. (2023a). DOI:<https://dx.doi.org/10.21123/bsj.2023.8214>
- [30] Obaid, Zahraa H., Jasim Mohammed Salman and Nuha F. Kadhim. Review on Toxicity and Removal of Pharmaceutical Pollutants Using Immobilised Microalgae. *Ecol. Eng. Environ. Technol.* 6:44–60. (2023b). DOI: <https://doi.org/10.12912/27197050/166013>
- [31] Mohamed-Ali, S. S., Salman, J. M., & Almamoori, A. M. A study of some environmental biomarkers in fresh water clam (*Unio tigridis*) and fresh water crab (*Sesarma boulengeri*) in Hilla river. *Mesopotamia Environmental Journal* (mesop. environ. j) ISSN: 2410-2598, 3(1), 45-59. (2016).
- [32] Baiee, M. A., & Salman, J. M. Effect of phosphorus concentration and light intensity on protein content of microalga *Chlorella vulgaris*. *Mesopotamia Environmental Journal* (mesop. environ. j) ISSN: 2410-2598, 2(2), 75-86. (2016).